

Case Report

Prosthetic management of a hemimandibulectomy patient using tilted implant protocol with 3-year follow-up

P. Venkat Ratna Nag^{1,2}, Tejashree Bhagwatkar³

¹Department of Prosthodontics, S B Patil Dental College and Hospital, Bidar, Karnataka, ²Director and ³Private Practice, Institute for Dental Implantology, Hyderabad, Telangana, India

Abstract

Surgical resection of the mandible due to the presence of benign or malignant tumor commonly results in the deviation of the remaining mandible toward the defective side. Based on the location and extent (mandible), various surgical approaches such as marginal, segmental, and hemi or subtotal or total mandibulectomy can be executed. The restoration of normal form, function, and esthetic is often challenging in the prosthetic rehabilitation of patients with hemimandibulectomy. A 36-year-old male patient reported with a chief complaint of difficulty in eating and speech. Past dental history of the patient revealed ameloblastoma of the left mandibular alveolus, which was surgically operated 6 years back with a wide resection of the tumor with left-sided hemimandibulectomy without disarticulation and reconstruction with an osteocutaneous free fibula flap (from the right leg) fixed with a screw plate system. This case report suggests that the rehabilitation of surgically resected patients using tilted implant technique can reach a desirable prosthetic outcome. This clinical report describes prosthetic management (implant-supported fixed prosthesis) of a hemimandibulectomy patient using tilted implants and screw-retained prosthetic solutions using multiunit abutments. It improves speech, masticatory efficiency, and esthetics without any further deviation of the mandible with a 3-year follow-up.

Keywords: Hemimandibulectomy, multiunit abutment, screw-retained prosthesis, tilted implant

Address for correspondence: Dr. P. Venkat Ratna Nag, Institute for Dental Implantology, 8-2-598/A/1, GB, Uma Devraj Villa, Road No. 10, Banjara Hills, Hyderabad - 500 034, Telangana, India.
E-mail: tdspublication@gmail.com

Submitted: 16-Oct-2019, **Revised:** 12-Mar-2020, **Accepted:** 15-May-2020, **Published:** 17-Jul-2020

INTRODUCTION

An ameloblastoma is a highly aggressive benign odontogenic tumor of epithelial origin, often asymptomatic, commonly located in the posterior mandible, and treated by surgical excision for extensive tumors.^[1] To overcome esthetic and functional disabilities caused by resection of tumor, reconstruction of the orofacial region has been proposed. The degree of impairment of mandible depends on

the extent and type of surgery, thus compromising the prognosis of the prosthetic rehabilitation to a greater extent.^[2] The debilitating sequences succeeding the surgical resection of mandible are impaired speech, mastication, difficulty in deglutition, decreased salivary secretions, poor appearance, and often leading to psychological disorders.^[2]

The rehabilitation of hemimandibulectomy patients in mandibular defect area with a fixed prosthesis is a

Access this article online	
Quick Response Code:	Website: www.j-ips.org
	DOI: 10.4103/jips.jips_415_19

This is an open access journal, and articles are distributed under the terms of the Creative Commons Attribution-NonCommercial-ShareAlike 4.0 License, which allows others to remix, tweak, and build upon the work non-commercially, as long as appropriate credit is given and the new creations are licensed under the identical terms.

For reprints contact: reprints@medknow.com

How to cite this article: Nag PV, Bhagwatkar T. Prosthetic management of a hemimandibulectomy patient using tilted implant protocol with 3-year follow-up. *J Indian Prosthodont Soc* 2020;20:326-30.

challenging task for dentists. The challenges that come across these patients include resected skin grafts, scar tissue, limited coordinative abilities, and resorbed ridges. This type of dysfunction radically alters the prosthetic prognosis.^[3] The most difficult condition is to treat hemimandibulectomy cases with deviation of mandible, due to many other factors such as extent of bone and soft-tissue involvement, loss of both sensory and motor innervations, type of wound closure, and other additional treatments.^[3] The tilted implant concept has been used for rehabilitation of edentulous maxillary and mandibular arches. The tilted implant concept is a graftless solution utilizing native bone, thus avoiding vital structures and also reducing stress while achieving bicortical engagement (by using longer implant),^[4] Minimizing stress at crestal cortical plate and by utilizing native bone which is highly resistant to infection resorption, transferring load from crestal to basal cortical bone, and anterioposterior can be selected engaging native basal bone which is highly mineralized, when engaged will be able to achieve high primary stability, a pre requisite for immediate loading helps in stabilization and elimination of cantilever is also possible. Numerous studies have evaluated tilted implant–prosthetic framework presenting success rates of 95%–100%. Babbush *et al.* performed a retrospective study on 165 patients (708 implants) and reported a cumulative survival rate of 99.6% (99.3% maxilla and 100% mandible), and the prosthesis survival rate was 100% for up to 2 years, 5 months of loading.^[5]

Criteria for success of implants (Schnitman and Shulman 1979) are as follows:^[6]

1. <1 mm implant mobility and absence of metallic sound
2. Zero bone loss
3. No radiolucency.

This case report describes prosthodontic management of a patient who has undergone a hemimandibulectomy and was rehabilitated using tilted implant-supported fixed prosthesis easy by converting bone level prosthesis to tissue level prosthesis.

CASE REPORT

A 36-year-old male patient reported with a chief complaint of difficulty in eating and speech. A complete case history was recorded, followed by a thorough intraoral examination. On eliciting history, the patient revealed a history of pain and swelling in the lower left side of the jaw 6 years back, which was diagnosed as ameloblastoma of left mandibular alveolus. The patient was surgically operated with a wide resection of the tumor with left-sided hemimandibulectomy without disarticulation

and reconstruction with an osteocutaneous free fibula flap (from the right leg) fixed with a screw plate system. Extraoral examination indicated facial asymmetry with a slight depression on the left side. Intraoral examination revealed absence of mandibular ridge extending posteriorly from the left central incisor region with missing teeth 31–37 [Figure 1a]; the remaining natural teeth in both arches were having good periodontal support. The patient was willing to have fixed prosthesis on the surgical site. A thorough radiographic evaluation was indicated. It includes orthopantomogram (OPG) [Figure 1b], computed tomography (CT), and stereolithography models. CT demonstrated good bony consolidation at the anterior and posterior margins of the graft with no abnormality detected. Considering the amount of bone, it was decided that placement of implants using the tilted concept was the best alternative, followed by fixed prosthesis. Routine blood investigations were done and fitness was obtained for surgical technique.

Patient consent was taken prior to the surgical procedure. Under aseptic condition, local anesthesia (2% lignocaine hydrochloride with adrenaline [1:200,000]) was given on the surgical site. A pilot drill of 1.2 mm [Figure 2a] was planned and inserted through the mucosa into the alveolar bone of 31, 33, 34, and 36 (four-implant placement) for point of entry to a depth of 6 mm. The single drill concept was followed, i.e., a long-stepped drill with diameters of 1.4–2.2 mm was used with enough coolant and angulation was confirmed using Radiovisiography (RVG.) Underdrilling concept, wherein the diameter of the drill is less than the implant to be placed for better anchorage and better osseococondensation, was done.

The Bioline-i-implants (Bioline Dental GmbH & Co.KG: Akazien str 7 16356, Wermeuchen, Germany) (3.75 mm in diameter and length 13 and 16 mm) were mounted on the implant driver, and a torque of 45 Ncm using a torque wrench was used for final placement of the implant with respect to teeth 31, 33, 34, and 36 [Figure 2b]. Multiunit abutments were placed at 8°, 30°, and 45° to compensate tilt of the implants, and parallelism was obtained [Figure 2c].

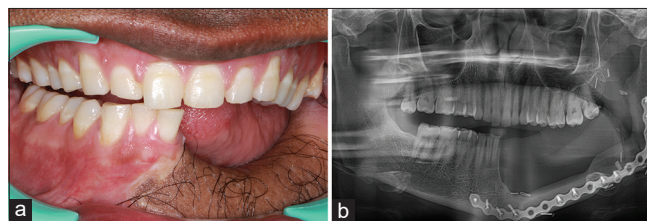


Figure 1: (a) Intraoral view showing missing 31–37. (b) Postsurgical panoramic radiograph showing reconstructed left mandible with a screw plate system used for fixation and osseous graft

Postimplant placement, OPG was exposed [Figure 3]. Multiunit healing caps were placed during a 3-month healing procedure. To avoid postoperative complications, antibiotics and analgesics were prescribed to the patient. The healing was uneventful, and sutures were removed after 10 days of the surgical procedure.

Two-step multiunit level open tray impressions were made with transfer copings. Jaw relations were taken; Malo bridge design was planned in this case. Porcelain-fused cobalt–chromium framework (direct metal laser sintering) printing metal framework was done. Secondary bite was taken with a bite registration material [Figure 4]. Shade selection was done using the VITA classical A1–D4® shade guide. Ceramic layering was done. Bisque trial was done after few days. Final occlusion adjustment was done and was sent to the laboratory for glazing. The patient was then rehabilitated with permanent screw-retained metal-ceramic fixed prosthesis [Figure 5a-c]. After prosthesis placement, OPG was exposed [Figure 6]. The

patient was advised to adhere to regular oral hygiene maintenance and regular follow-up. The patient was followed up after 3 months, 6 months, 1 year, and 3 years. After a 3-year follow-up [Figure 7a], the patient presented with implant stability and adequate occlusal relationship. OPG [Figure 7b] revealed no peri-implant bone loss or inflammation and properly osseointegrated with the bone (implant stability).

DISCUSSION

Ameloblastomas are benign odontogenic tumors that develop from the epithelial rests of Malassez. It is slowly developing, aggressively infiltrating into trabecular bone that results in local hard- and soft-tissue deformities. The only treatment modality available is surgical resection, followed by the mandibular bone reconstruction with free fibula osteocutaneous flap.^[7]

Dental implant insertion into reconstructed mandibles is one of the most challenging procedures for dental surgeons. In literature, the treatment option for hemimandibulectomy patients was removable prosthesis, which shows limited

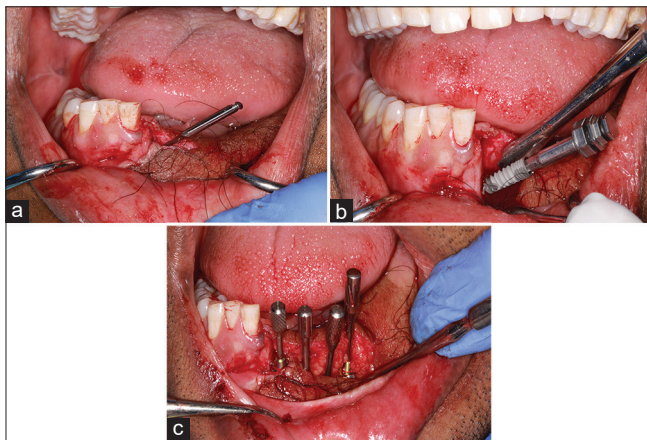


Figure 2: (a) Pilot drill of 1.2 mm was inserted through the mucosa into the alveolar bone. (b) Placement of Bioline-i-implant. (c) Multiunit abutments were placed, and parallelism was obtained

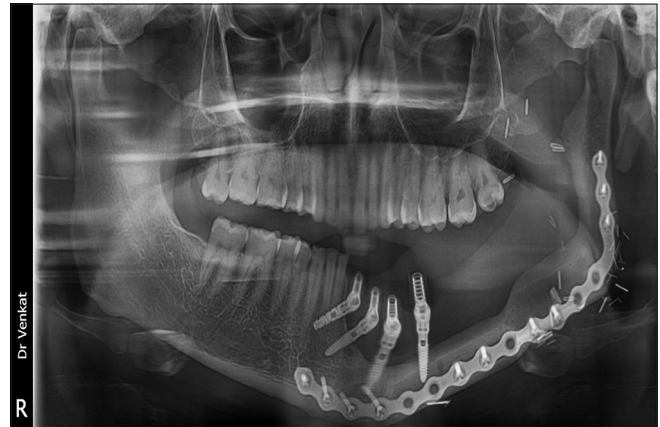


Figure 3: Postimplant placement orthopantomogram

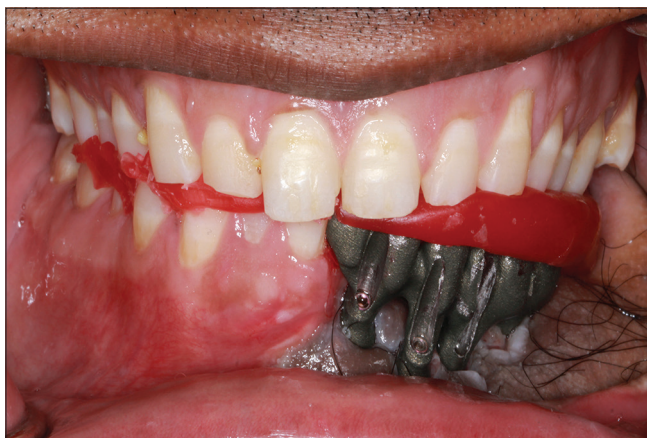

Figure 4: Metal framework trial and the secondary bite was taken with bite registration material

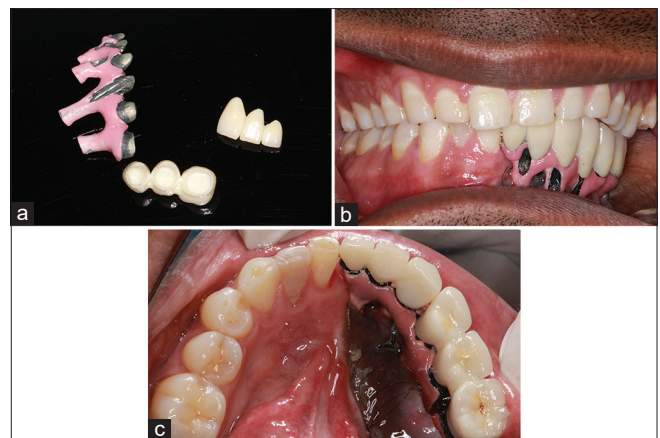


Figure 5: (a) Malo bridge. (b and c) Final metal–ceramic prosthesis

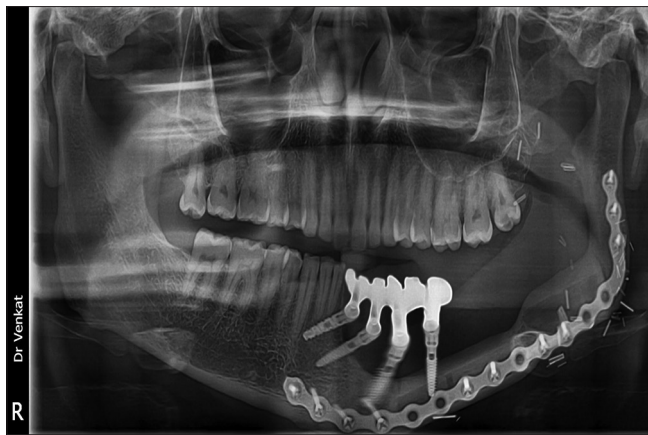

Figure 6: Orthopantomogram with implant and prosthesis

functional and esthetic values, whereas few were based on mandibular reconstruction with free bone grafts and tilted implants with fixed prosthesis.^[1,3,4]

Introduction of the tilted implant concept shows many advantages such as bypass anatomical structures, stability even in minimum bone volume, reduces the length of cantilevers, and better loading stress distribution.^[4] Tilted implant placement with immediate loading protocol is the best solution for mandibular reconstruction in hemimandibulectomy patients. In this case, the tilted implant concept used for mandibular reconstruction showed good results with better implant survival even after a 3-year follow-up. The use of tilted implants lowers the mechanical stresses on the peri-implant bone with respect to vertical implant using finite element analysis. It provides fixed prosthetic solutions with more comfortable and significantly improved function and esthetics.^[4]

Francetti *et al.* performed a prospective study on tilted and axially placed implant for the rehabilitation of the mandible. They found immediate loading associated with tilted implant advocated as a viable treatment modality for mandibular rehabilitation.^[8] Ivanoff *et al.* performed a study to evaluate bone tissue response to titanium implants supported by mono- and bicortical engagement and found that bicortical anchorage of implants can be used in the clinical situation.^[9] Pai *et al.* reviewed on osseodensification and found this specialized procedure used for osteotomy preparation improved bone density, increase percentage bone volume and bone to implant contact which improve implant stability helps in osseointegration. Tilted implant concept follows osseodensification for osteotomy preparation due to many advantages.^[10]

Degidi *et al.* performed a study to assess the effects of abutment removal after 6 months on bone healing after

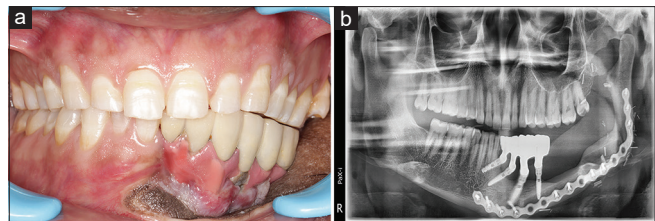


Figure 7: (a) Intraoral view after a 3-year follow-up. (b) Postoperative orthopantomogram after 3-year follow-up

subcrestal placement for partial edentulism. They concluded that nonremoval of abutment placed at the time of surgery reduces horizontal bone reduction.^[11] Torrecillas-Martínez *et al.* conducted a review and meta-analysis to evaluate the influence of cantilever on marginal bone loss and prosthetics. They found that minor technical complications were found when cantilever was present when compared to noncantilever.^[12] Prognosis of all the remaining teeth was fair in relation to the clinical and radiographic evaluation.

Limitations of this case were as follows:

1. Cost factor as multiunit abutment was used to convert bone level to tissue level of implant prosthesis junction, which was considered as an additional bone component
2. Gross facial deviation cannot be compensated using this technique.

CONCLUSION

The present clinical report supported the use of tilted implant concept for definitive patient rehabilitation with a reconstructed mandible along with immediate loading with fixed screw-retained prosthesis. Minimal surgical complications, good implant and prosthesis survival rate, and improved oral hygiene suggest that the use of tilted implants is a predictable technique for prosthetic rehabilitation of the edentulous mandible. It has proven to be a clinically effective technique, which appears very comfortable for a patient both in the functional and esthetic sense.

Financial support and sponsorship

Nil.

Conflicts of interest

There are no conflicts of interest.

REFERENCES

1. Patil PG, Patil SP. Guide flange prosthesis for early management of reconstructed hemimandibulectomy: A case report. *J Adv Prosthodont* 2011;3:172-6.
2. Ahuja A, Jagadeesh HG, Choudhary A, Vikram J, Hasti A. Prosthetic management of hemimandibulectomy patient-a case report. *IOSR*

Nag and Bhagwatkar: Prosthetic management of a hemimandibulectomy patient using tilted implant

- J Dent Med Sci 2015;14:94-6.
3. Gandhimathi J, Krishnameera N, Sriramprabu G, Vinayagavel K, Sabarigirinathan C, Rupkumar P, *et al.* A systematic approach for functional rehabilitation of hemimandibulectomy patient. *Int J Oral Health Med Res* 2015;2:60-2.
 4. Venkat Nag P, Sarika P, Bhagwatkar T, Dhara V. Tilted implant placement for rehabilitation of severe atrophic maxilla supported by finite element analysis. *J Implant and Adv Clin Dent* 2019;11:14-25.
 5. Babbush CA, Kutsko GT, Brokloff J. The all-on-four immediate function treatment concept with NobelActive implants: a retrospective study. *J Oral Implantol* 2011;37:431-45.
 6. Zarb CA, Albrektsson T. Nature of implant attachment. In: Branemark PI, Zarb V, Albrektsson T, editors. *Tissue Integrated Prostheses. Osseointegration in Clinical Dentistry*. Chicago: Quintessence Publishing. Co.; 1985. p. 88-98.
 7. Marathe AS, Kshirsagar PS. A systematic approach in rehabilitation of hemimandibulectomy: A case report. *J Indian Prosthodont Soc* 2016;16:208-12.
 8. Francetti L, Agliardi E, Testori T, Romeo D, Taschieri S, Del Fabbro M. Immediate rehabilitation of the mandible with fixed full prosthesis supported by axial and tilted implants: interim results of a single cohort prospective study. *Clin Implant Dent Relat Res* 2008;10:255-63.
 9. Ivanoff CJ, Sennerby L, Lekholm U. Influence of mono-and bicortical anchorage on the integration of titanium implants. A study in the rabbit tibia. *Int J Oral Maxillofac Surg* 1996;25:229-35.
 10. Pai UY, Rodrigues SJ, Talreja KS, Mundathaje M. Osseodensification-A novel approach in implant dentistry. *J Indian Prosthodont Soc* 2018;18:196-200.
 11. Degidi M, Nardi D, Piattelli A. One abutment at one time: non-removal of an immediate abutment and its effect on bone healing around subcrestal tapered implants. *Clin Oral Implants Res* 2011;22:1303-7.
 12. Torrecillas-Martínez L, Monje A, Lin GH, Suarez F, Ortega-Oller I, Galindo-Moreno P, *et al.* Effect of cantilever for implant supported prostheses on marginal bone loss and prosthetic complications: Systematic review and meta analysis. *Int J Oral Maxillofac implants* 2014;29:1315-21.